

## Comparison of Various Staining Methods to Detect Helicobacter Pylori

Rashmi Monteiro<sup>1</sup>, Shivashekar Ganapathy<sup>2</sup>, Bhuvanamha Devi R.<sup>3</sup>, Sandhya V.<sup>4</sup>

<sup>1</sup>Postgraduate <sup>2</sup>Professor and Head <sup>3</sup>Assistant Professor <sup>4</sup>Professor, Department of Pathology, SRM Medical College Hospital & Research Centre, SRM Nagar, Potheri, Kattankulathur, Kancheepuram, Tamil Nadu 603203, India.

### Abstract

*Context:* Helicobacter pylori (H. pylori) is the major cause of chronic gastritis, peptic ulcer and gastric cancer. It causes varied histological derangements & hence the detection of H. pylori is important.

*Aims:* The study was done to evaluate the efficacy of various stains- Hematoxylin & Eosin (H & E), modified Giemsa and Immunohistochemistry (IHC) in the detection of H. pylori and to correlate the H. pylori positivity with histological changes.

*Settings and Design:*

*Methods and Material:* 100 samples of gastric biopsy & resected specimen were studied with H & E, modified Giemsa and IHC stain. Detection of the organism & associated morphological changes were assessed. The stains were validated using IHC as gold standard.

*Statistical analysis used:* Comparison between the stains were assessed using chi square test.

*Results:* Out of 100 cases, 67 showed positivity with IHC & 58 and 63 were positive with H & E and modified Giemsa respectively. Sensitivity and specificity of H & E was 86.6% and 100% & modified Giemsa was 94% and 100% respectively. Mononuclear infiltrate were noted in 67 cases with H. pylori infection. Similarly in 61 cases with neutrophil activity, 12 cases with atrophy and 4 cases with intestinal metaplasia showed associated H. pylori infection.

*Conclusions:* Modified Giemsa stain is less time consuming, cost effective and easily available when compared to IHC but IHC can detect mild infection, where H & E and modified Giemsa are negative.

**Keywords:** Gastritis; H. pylori; H & E; Immunohistochemistry; Modified Giemsa.

### Corresponding Author:

**Shivashekar Ganapathy**, Department of Pathology, SRM Medical College Hospital & Research Centre, SRM Nagar, Potheri, Kattankulathur, Kancheepuram, Tamil Nadu 603203, India.

**E-mail:** vpsrmmmedical@yahoo.co.in

**Received on** 12.02.2019,

**Accepted on** 07.03.2019

### How to cite this article:

Rashmi Monteiro, Shivashekar Ganapathy, Bhuvanamha Devi R. et al. Comparison of Various Staining Methods to Detect Helicobacter Pylori. Indian J Pathol Res Pract. 2019;8(2):218-222.

## Introduction

Helicobacter pylori (*H. pylori*) is a common infection worldwide infecting more than half of the world's population with a prevalence of 25% in developed countries and 90% in developing countries [1]. Therefore the risk of *H. pylori* infection is higher among people in developing countries. Helicobacter pylori was classified as class I carcinogen in humans by The International Agency for Research on Cancer (IARC) an organization of the World Health Organization (WHO) [2]. It is therefore important to diagnose *H. pylori* due to its relationship with gastroduodenal diseases and malignancies. *H. pylori* is difficult to be identified on Hematoxylin and Eosin (H & E) stain, especially with low density of the organism. Demonstration can be enhanced by using histochemical and immunohistochemical (IHC) stains [3]. But various studies show varying results regarding efficacy of these stains. We studied the efficacy of H & E and modified Giemsa stain in demonstration of *H. pylori* as compared to Immunohistochemistry (Anti-*H. pylori* antibody) and correlated *H. pylori* positivity with various histological changes.

## Materials and Methods

The present study was conducted in the Department of Pathology SRM MCH & RC, Potheri, Chennai. This was a cross sectional study from August 2016- August 2018. Samples that were adequate and available for atleast 3-4 sections of 3-5 microns thickness were included in the study and samples of inadequate material and non-viable tissue were excluded. 100 cases were selected randomly from patients who underwent endoscopic gastric and duodenal biopsies and resected specimens of stomach and duodenum for various gastroduodenal lesions. 100 cases of gastric biopsies were selected randomly from the specimens received. Specimens were processed according to institutional standardized operating procedure. In addition to the routine Hematoxylin and Eosin, modified Giemsa and IHC were done on the sections of each case and they were subsequently examined. Morphological changes were assessed on H & E stained slides. Categories described by the Updated Sydney System- *H. pylori* density, neutrophil infiltration, mononuclear infiltration, atrophy and intestinal metaplasia were evaluated and graded into mild, moderate and severe [4,5]. The scoring of *H. pylori* density was done on each stain and were validated using the gold standard, Immunohistochemical stain. Statistical

analysis was done using SPSS software version 17.0. Chi square test was used for the comparison between two proportions. p value < 0.05 was considered to be statistically significant.

## Results

### *Comparison of IHC with Hematoxylin and Eosin & Modified Giemsa Stains*

Of the 100 cases 67 cases were positive and 33 cases were negative for *H. pylori* by IHC (Fig. 1). *H. pylori* was detectable with H & E stain (Fig. 2) in 58 cases, similarly in 63 cases with modified Giemsa stain (Fig. 3). 9 cases which were negative on H & E stain and 4 cases negative on modified Giemsa stain were found to be positive on IHC. 33 cases were negative in all stains. Sensitivity and specificity of H & E was 86.6% & 100% and modified Giemsa was 94.0% & 100% respectively. Related data is given in Table 1.

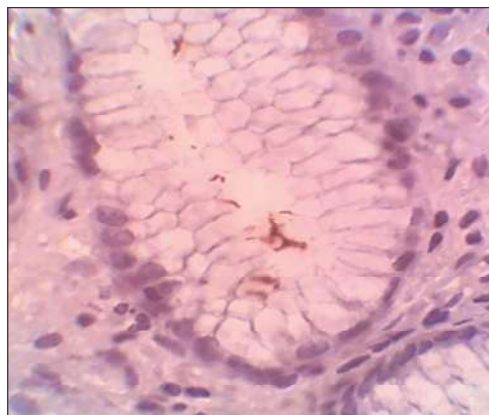

Fig. 1: Gastric pit and glands with mild *H. pylori* density, IHC x1000

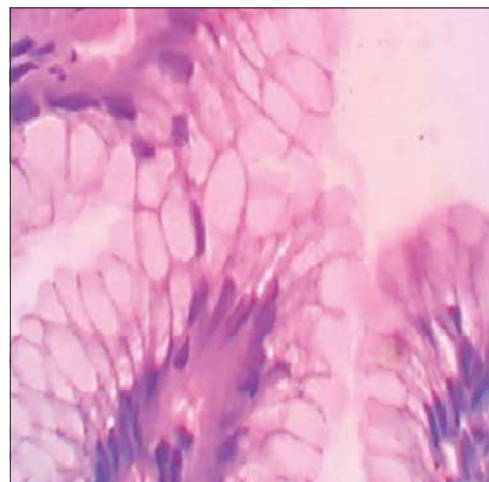
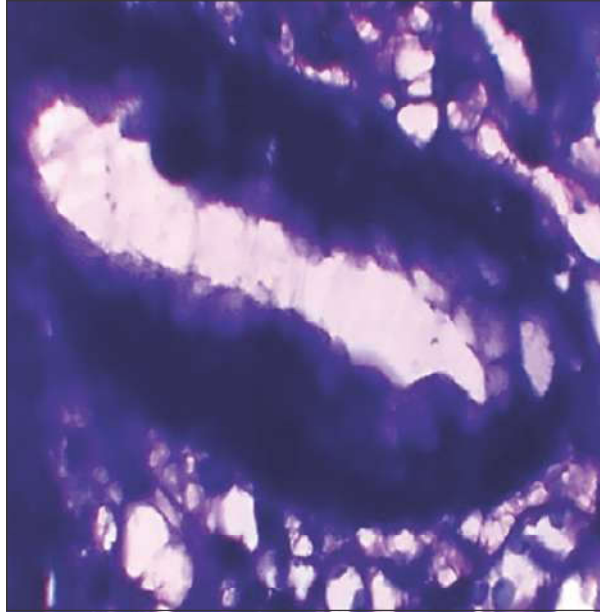


Fig. 2: Gastric mucosa showing mild *H. pylori* density, H & E x1000



**Fig. 3:** Gastric mucosa with mild *H. pylori* density, modified Giemsa x1000

them were positive for *H. pylori*. The p value was 0.470. Atrophy and intestinal metaplasia showed no significant association with *H. pylori* positivity. Related data as well as result of analysis are given in Table 2.

### Discussion

In the current study, the sensitivity of H & E for detection of *H. pylori* organism was 86.6% and specificity was 100% which was consistent with study done by Priyadarshini M et al. [6] and Elias DRE et al. [7]. Specificity and sensitivity was lower in Pity IS et al. [8] and Sharma RP et al. [9]. Low sensitivity may be explained due to the lack of contrast between the bacilli and the surrounding tissue and the bacilli often being confused with debris and mucus seen in H & E stain [9]. However, study done by Wang XI et al. [10] found that H & E stain was sufficient for detecting *H. pylori*.

In our study, modified Giemsa stain showed

**Table 1:** Comparison between IHC and H & E & IHC and modified Giemsa.

Stains	IHC		Stains	IHC	
H & E	Positive (n=67)	Negative (n=33)	Modified Giemsa	Positive (n=67)	Negative (n=33)
Positive (n=58)	58	0	Positive (n=63)	63	0
Negative (n=42)	9	33	Negative (n=37)	4	33

**Table 2:** Association of various histological features with *H. pylori* positivity.

Histological features	H. pylori		Chi square	p value
	Positive	Negative		
Neutrophil activity (n=67)	61	6	54.087	0.0001
Mononuclear infiltrate (n=97)	67	30	23.677	0.0001
Atrophy (n=14)	12	2	2.606	0.272
Intestinal metaplasia (n=6)	4	2	1.508	0.470

#### *Association of Histological Changes with H. pylori Positivity According to "Updated Sydney System"*

Of the 100 cases, 67 cases showed activity and 61 (91.04%) cases among them were positive for *H. pylori*. The p value obtained was 0.0001, which was statistically significant. 97 cases showed mononuclear infiltrate and 67 (69.07%) cases among them were positive for *H. pylori*. The association between mononuclear infiltrate and *H. pylori* shows a significant p value of 0.0001. Out of 100 cases, 14 cases showed atrophy and among them 12 (85.71%) cases were positive for *H. pylori*. The p value calculated was 0.272. 6 cases showed intestinal metaplasia and 4 (66.67%) cases among

94% sensitivity and 100% specificity. These findings were similar to Priyadarshini M et al. [6], Shukla S et al. [11] and Bamanikar S et al. [12]. Lower sensitivity in studies conducted by Hartman and Owens [13] and Pity IS et al. [8] has been explained due to the similar blue colour of the bacilli and the gastric tissue which makes it difficult to identify the organism when the bacterial load is low [9].

Association of *H. pylori* positivity with the neutrophilic activity was statistically significant. Similar findings were noted by Palaniappan VM et al. [14]. Pity IS et al. [8] showed 67.1% and Maharjan S et al. [15] showed 64.8% *H. pylori* positivity associated with activity.

In our study, 67 (69.07%) out of 97 cases showing mononuclear infiltrate were positive for H.pylori and their association was statistically significant. This was similar to the results showed in Pity IS et al [8] and Maharjan S et al. [15]. On the contrary, Tanko MN et al. [16] showed increased number of H. pylori positivity in cases with mononuclear infiltrate 79 (83.2%).

In the current study, no statistically significant association was seen between atrophy and H. pylori positivity. Other studies by Tanko MN et al. [16], Maharjan S et al. [15] and Sharma RP et al. [9] have also reported similar findings. We also noted that H.pylori was not found in atrophic glands but was present in non atrophic glands in the same section. Tanko MN et al. [16] explains it due to decrease of mucus secretion in atrophic glands that provides an unsuitable environment for H. pylori colonization.

Our study showed 6 cases with intestinal metaplasia and among them H. pylori infection was noted in 4 cases (66.67%). This association was not statistically significant. Maharjan S et al. [15] and Pity IS et al. [8] had similar findings, while Sharma RP et al. [9] had no cases of intestinal metaplasia (12cases) positive with H. pylori infection (0.0%).

### Conclusion

H.pylori infection should be evaluated thoroughly with special histochemical stains when histological features show neutrophilic activity and mononuclear infiltrate.

In our study, cases with intestinal metaplasia showing H. pylori infection was noted in the non-metaplastic areas of the same section. Hence, we recommend special stains to be definitely used in such cases, where H. pylori are not detectable on routine H & E.

Though modified Giemsa stain is simple, economical, rapid and can be used routinely, it does not provide contrast to the bacilli and cases with low bacillary load are not easily detectable with modified Giemsa stain. In such cases IHC is recommended.

With the application of IHC even mild H. pylori density or indolent forms of H. pylori can be detected with ease, providing early diagnosis and treatment to H. pylori associated gastritis.

### Key Messages

Negative cases with strong clinical suspicion, low density and indolent forms of the bacteria, where H

& E and modified Giemsa have low detection rate, IHC should be recommended for detection of H. pylori.

### References

1. Mnena EY, Ebele U, Emmanuel N. Risk Factors Associated with Helicobacter Pylori Infections in MakurdiNorthcentral Nigeria. *J Infect Dis Ther.* 2017;5(325):2332-0877.
2. Kabamba ET, Tuan VP, Yamaoka Y. Genetic populations and virulence factors of Helicobacter pylori. *Infection, Genetics and Evolution.* 2018; 60:109-16.
3. Lee JY, Kim N. Diagnosis of Helicobacter pylori by invasive test: histology. *Annals of translational medicine.* 2015;3(1).
4. Carrasco G, Corvalan AH. Helicobacter pylori-Induced Chronic Gastritis and Assessing Risks for Gastric Cancer. *Gastroenterology Research and Practice.* 2013;2013:1-8.
5. Chen XY, van Der Hulst RW, Bruno MJ, van der Ende A, Xiao SD, Tytgat GN, Ten Kate FJ. Interobserver variation in the histopathological scoring of Helicobacter pylori related gastritis. *Journal of clinical pathology.* 1999;52(8):612-5.
6. Priyadharshini M, Sindu V. A comparative study between immunohistochemistry, hematoxylin& eosin and geimsa stain for helicobacter pylori detection in chronic gastritis. *International Journal of Pharma and Bio Sciences.* 2017;8(1):727-33.
7. Elias DRE, Gisuthan B, Raj M.L DD. Role of Special Stain Giemsa in Demonstration of Helicobacter Pylori in Gastric Biopsies. *Journal of medical science and clinical research.* 2017;5(8).
8. Pity IS, Baizeed AM. Identification of helicobacter pylori in gastric biopsies of Patients with chronic gastritis: histopathological and Immunohistochemical study. *Duhok Med J.* 2011; 5(1):69-77.
9. Sharma RP, Kumari MKK. Histological identification of Helicobacter pylori: comparison of staining methods. *International Journal of Medical Research and Review.* 2015;3(10):1167-73.
10. Wang XI, Zhang S, Abreo F, Thomas J. The role of routine immunohistochemistry for Helicobacter pylori in gastric biopsy. *Annals of diagnostic pathology.* 2010;14(4):256-9.
11. Shukla S, Pujani M, Agarwal A, Pujani M, Rohtagi A. Correlation of serology with morphological changes in gastric biopsy in Helicobacter pylori infection and evaluation of immunohistochemistry for H. pylori identification. *Saudi J Gastroenterol.* 2012;18:369-74.
12. Bamanikar S, Khandelwal A, Shah K et al. Detection of helicobacter pylori in gastric biopsies of patients

- with chronic gastritis: histopathological and immunohistochemical study. *Int J Health Sci Res.* 2018;8(3):39-47.
13. Hartman DJ, Owens SR. Are routine ancillary stains required to diagnose *Helicobacter* infection in gastric biopsy specimens? An institutional quality assurance review. *American journal of clinical pathology.* 2012;137(2):255-60.
  14. Palaniappan VM, VenkatramanJanarthanam MD, Swaminathan KM. Histomorphological profile of Gastric antral mucosa in *Helicobacter* associated gastritis. *Int. J. Curr. Res. Med. Sci.* 2016;2(4):22-8.
  15. Maharjan S, Ranabhat S, Tiwari M, Bhandari A, Osti BP, Neopane P. *Helicobacter Pylori* Associated Chronic Gastritis and Application of Visual Analogue Scale for the Grading of the Histological Parameters in Nepal. *Biomedical Journal of Scientific & Technical Research.* 2017;1(1).
  16. Tanko MN, Manasseh AN, Echejoh GO, Mandong BM, Malu AO, Okeke EN, Ladep N, Agaba EI. Relation between *Helicobacter pylori*, inflammatory (neutrophil) activity, chronic gastritis, gastric atrophy and intestinal metaplasia. *Nigerian journal of clinical practice.* 2008;11(3):270-4.
-